

Clustering syncope in a young male with temporal lobe seizures

Fanny Dubois-Teklali* MD;
Marie-Ange Nguyen-Morel MD, Paediatric Department;
Wilfried Vadot MD, Functional Exploration of Nervous System, Department of Neurology;
Stephanie Douchin MD, Paediatric Department;
Pascal Defaye MD, Cardiac Stimulation and Rhythmology Unit, Cardiology Department;
Laurent Vercueil MD, Functional Exploration of Nervous System, Department of Neurology, Grenoble University Hospital, Grenoble, France.

*Correspondence to first author at Paediatric Department, Grenoble University Hospital, BP 217 38043, Grenoble Cedex 09, France.
E-mail: fdubois@chu-grenoble.fr

We report the case of a male aged 2 years 6 months with left temporal lobe epilepsy who presented with ictal bradycardia syndrome leading to asystole. The clinical presentation was remarkable for the occurrence of clustering syncope. A seizure was recorded on a video electroencephalogram–electrocardiogram and analyzed. A cardiac pacemaker was implanted and antiepileptic drug treatment was initiated. We suggest that clustering of syncope is an important feature in the presentation of epilepsy in a young child.

Ictal sinus bradycardia leading to asystole has been well described in adult patients with refractory temporal lobe epilepsy. It has been suggested as one of the major causes of sudden unexplained death in patients with epilepsy (Rocamora et al. 2003). Although the frequency of death has been reported to be 8.8-fold higher in children with epilepsy than in a reference population (Camfield et al. 2002), ictal asystole during a seizure is rare in young children. Two case reports have been published (Venugopalan et al. 2001, Seeck et al. 2003). The present case is of particular interest for the following reasons: (1) the diagnosis of epilepsy was difficult because of the atypical presentation; (2) recordings were made of electroencephalogram (EEG), electrocardiogram (ECG), and video simultaneously during a seizure with asystole; and (3) there are therapeutic implications that arise from this particular example.

Case report

The patient was a male aged 2 years 6 months, the third of three siblings. There was no family history of seizure or learning disability.* His past medical history was remarkable for a preterm birth at 36 weeks leading to hospitalization in the neonatal intensive care unit for 28 days for neonatal respiratory distress. He was also treated for anaemia and gastroesophageal reflux disease during the first 3 months of life and then for asthma. His early development milestone was slightly delayed (he walked at 19mo).

At the age of 1 year 9 months he experienced four paroxysmal events at home in a single day, with pallor, cyanosis of the lips, and loss of consciousness for 1 minute, followed by

*North American usage: mental retardation.

transient hypotonia. No abnormal movement was described. At the emergency department, his clinical examination, ECG, and EEG were normal. These events recurred twice, 3 weeks and 4 months later. All investigations, including repeated ECG with QT calculation and oculocardiac reflex, EEG, echocardiography, 24- and 48-hour Holter ECG, metabolic profile, and oesophageal pH monitoring, were normal. No treatment was initiated.

At the age of 2 years 4 months, the same events recurred. One of these occurred during a video EEG–ECG, enabling the diagnosis of a temporal lobe seizure. Clinically, the onset of the seizure was asymptomatic, the child remained awake and interacted with his mother. A brief tonic phase (extension of the upper limbs) occurred lasting for 10 seconds associated with apnoea. He then developed extreme high pallor, cyanosis, and a marked loss of tone for 5 minutes. He remained hypotonic for more than 1 hour postictally.

The ictal EEG was first characterized by 3Hz high-amplitude

rhythmic sharp waves over the left temporal areas (Fig. 1a), which quickly spread to the two hemispheres. At 1 minute after seizure onset (Fig. 1b), the entire recording flattened out during the tonic phase. At the end of the tonic phase, the baseline sinus rate of 110 to 120 beats/min suddenly decreased by 60 beats/min for 20 seconds and then asystole occurred for at least 20 seconds (Fig. 1c; definite onset of the asystole was difficult to determine because of the artefact during the tonic phase), and the heart rate slowly returned to baseline after 20 seconds of bradycardia. During bradycardia and asystole, the background EEG activity was depressed and then replaced by symmetrical and diffuse two to three slow waves. All the interictal EEGs were normal.

Normal brain magnetic resonance imaging excluded focal dysplasia.

Antiepileptic drug therapy was begun with sodium valproate (30mg/kg twice daily). Three months later, the same seizures recurred three times in 1 day despite therapy. Two

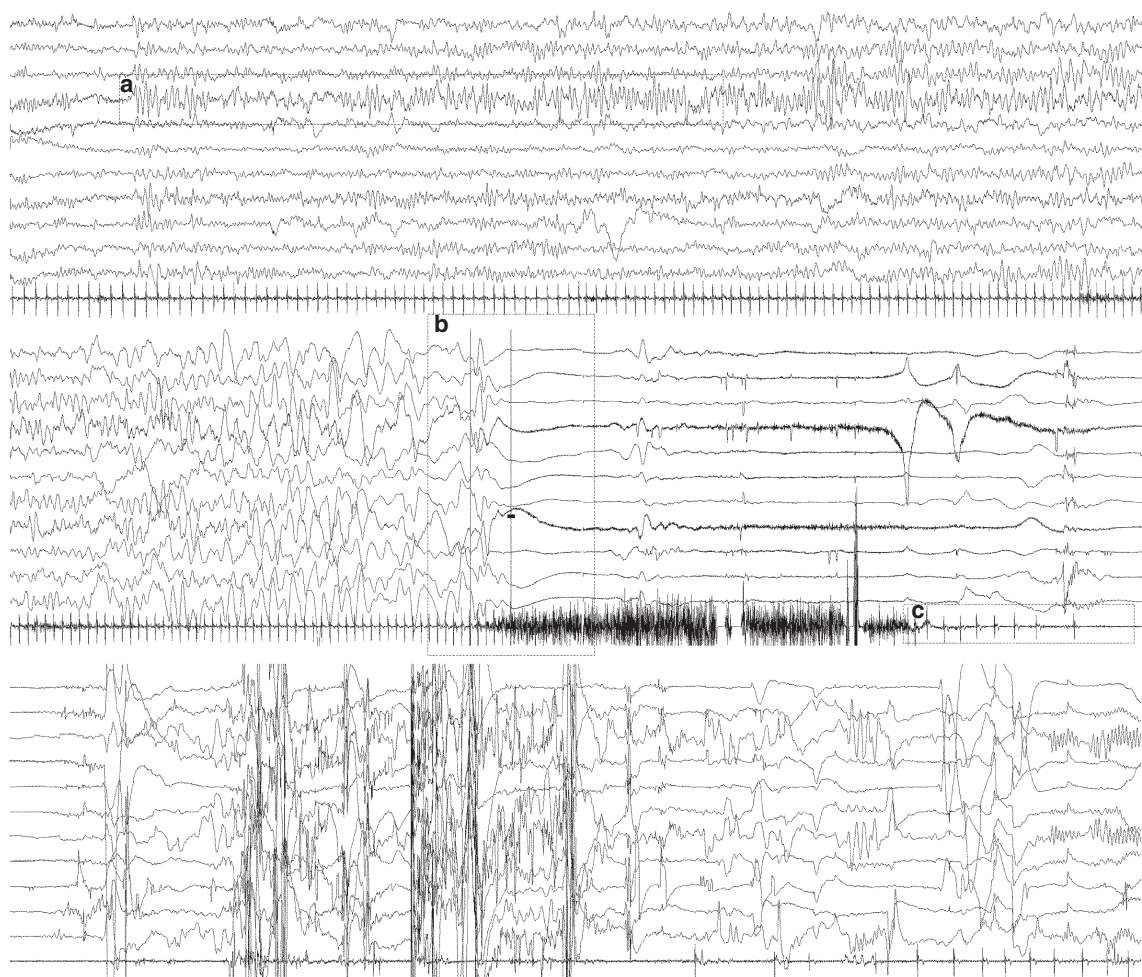


Figure 1: Ictal asystole recorded by video EEG–ECG. (a) Seizure onset with rhythmic sharp activity on left temporal electrode. (b) Tonic seizure with sudden diffuse flattening of EEG. (c) Bradycardia onset followed by asystole. EEG montage indicated to left. ECG tracing on bottom. EEG: filters, 0.3 second, 15Hz (notch 50Hz); amplitude, 30 μ V/mm. ECG: filters, 0.01 second, 15Hz; amplitude, 30 μ V/mm. EEG, electroencephalogram; ECG, echocardiogram.

severe seizures associated with bradycardia were witnessed by the medical staff. Oxcarbazepine (10mg/kg twice daily) was added to the treatment.

A permanent epicardial ventricular pacemaker (St Jude Microny, St Paul, Minnesota, USA) was implanted and programmed in VVI mode at 70 beats/min. Sleep respiratory activity was monitored at home to explore possible ictal apnoea. During the follow-up period, no clinical seizures were reported.

Discussion

Ictal bradycardia and asystole are rare in paediatric patients. As far as we know, this is the first case of a child with temporal lobe seizure and asystole recorded on a video EEG–ECG.

Venugopalan et al. (2001) reported a 5-month-old female with ictal asystole presumably related to temporal lobe seizure. However, they did not report simultaneous EEG and ECG during the seizure. Seeck et al. (2003) described a female aged 3 years 6 months with temporal lobe seizure with vegetative symptoms (facial flush, piloerection over both legs, and bradycardia). Her seizures were secondary to focal cortical dysplasia and 75% of 26 recorded seizures were associated with brief ictal bradycardia without true syncope. Epilepsy surgery was performed.

In the present case, the diagnosis of seizures was difficult. Clinically, the patient presented syncopes with pallor, cyanosis, and loss of consciousness, and required complete cardiologic and neurological investigations. Reeves et al. (1996) gave the name ictal bradycardia syndrome to this episode of loss of consciousness during a seizure. Abnormal heart rate, blood pressure, vasomotor tone, and respiratory variability during seizures were described in adult patients with frontal and temporal lobe seizures (Tinuper et al. 2001) and more recently in children (O'Regan and Brown 2005), but the pathophysiology is still debated. The propagation of seizure activity to cardiac chronotropic regions of the cortex and particularly to the insula is assumed to be involved in ictal bradycardia and asystole (Cheung and Hachinski 2000). Vegetative responses have been demonstrated by stimulation of the insula cortex in rats and by a stimulation study of the insula in human epilepsy patients undergoing presurgical evaluation for refractory epilepsy (Oppenheimer and Cechetto 1990, Oppenheimer et al. 1992).

These ictal vegetative dysfunctions are assumed to have a role in the pathogenesis of sudden unexplained death in epilepsy (Nei et al. 2004). Documenting ictal bradycardia and asystole during epileptic seizures is relevant in patient management to prevent potentially life-threatening events. However, this could be a very challenging option, given that seizures are unforeseeable. In the present case, the clustering of clinical events provided the opportunity to record a seizure.

In the present patient, a pacemaker implantation was debated because this procedure is invasive and carries the possibility of many adverse events such as infection. Moreover, at the time of diagnosis the patient was not receiving antiepileptic drugs, and it seemed logical to propose drug treatment before considering the epilepsy to be refractory. The child was, therefore, treated with sodium valproate. The preferred antiepileptic drug for patients with ictal cardiac bradyarrhythmia has not been determined. Carbamazepine can lengthen the QT interval and may increase the arrhythmic effects of epileptic seizures in adults. However, for an infant with normal cardiac results

(normal QT) and in sinus bradycardia, toxicity has not been demonstrated (Kwon et al. 2004). Subsequently, given the risk of relapse of the same clinical seizure in spite of treatment, a pacemaker was implanted.

In the case reported by Venugopalan et al. (2001), the young child died despite a normal-demand pacemaker during supposed temporal lobe seizure. A prolonged episode of apnoea associated with bradycardia secondary to a profound autonomic disturbance may have been the cause of death. In our case it was difficult to determine whether prolonged apnoea occurred during the seizure because of the artefact. In the future it will be important to document whether ictal apnoea occurs despite cardiac stimulation, the purpose of the patient's home respiratory monitoring. Moreover, pulse oximetry monitoring prevents the consequence of a prolonged episode of apnoea.

We report the case of a temporal lobe seizure with symptomatic and documented ictal asystole in a young child who presented with clustering syncopes. This case illustrates the importance of recording clinical events on video EEG–ECG to confirm the diagnosis of seizure and prevent life-threatening events. Moreover, we suggest that syncope clusters are indicative of the epileptic nature of paroxysmal events.

DOI: 10.1017/S0012162206001447

Accepted for publication 9th November 2005.

Acknowledgements

We thank P Plouin, O Dulac, and E Villain, Necker Hospital Paris, for their advice on this case.

References

- Camfield CS, Camfield PR, Veugelers PJ. (2002) Death in children with epilepsy: a population-based study. *Lancet* **359**: 1891–1895.
- Cheung RTF, Hachinski V. (2000) The insula and cerebrogenic sudden death. *Arch Neurol* **57**: 1685–1688.
- Kwon S, Lee S, Hyun M, Choe B, Kim Y, Park W, Cho Y. (2004) The potential for QT prolongation by antiepileptic drugs in children. *Pediatr Neurol* **30**: 99–101.
- Nei M, Ho RT, Abou-Khalil W, Drislane FW, Liporace J, Romeo A, Sperling MR. (2004) EEG and ECG in sudden unexplained death in epilepsy. *Epilepsia* **45**: 338–345.
- Oppenheimer SM, Cechetto DF. (1990) Cardiac chronotropic organization of the rat insular cortex. *Brain Res* **533**: 66–72.
- Oppenheimer SM, Gelb A, Gervin JP, Haschinski VC. (1992) Cardiovascular effects of human insular cortex stimulation. *Neurology* **42**: 1727–1732.
- O'Regan M, Brown JK. (2005) Abnormalities in cardiac and respiratory function observed during seizures in childhood. *Dev Med Child Neurol* **47**: 4–9.
- Reeves AL, Nollet KE, Klass DW, Sharbrough FW, So EL. (1996) The ictal bradycardia syndrome. *Epilepsia* **37**: 983–987.
- Rocamora R, Kurthen M, Lickfett L, Von Oertzen, Elger CE. (2003) Cardiac asystole in epilepsy: clinical and neurophysiologic features. *Epilepsia* **44**: 179–185.
- Seeck M, Zaim S, Chaves-Vischer V, Blanke O, Maeder-Ingvar M, Weissert M, Roulet E. (2003) Ictal bradycardia in a young child with focal cortical dysplasia in the right insular cortex. *Eur J Paediatr Neurol* **7**: 177–181.
- Tinuper P, Bisulli F, Cerollu A, Carcangiu R, Marini C, Pierangeli G, Cortelli P. (2001) Ictal bradycardia in partial epileptic seizures. Autonomic investigation in three cases and literature review. *Brain* **124**: 2361–2371.
- Venugopalan P, Nair PMC, Koul RL. (2001) An infant with seizure-related bradycardia and asystole. *J Pediatr Child Health* **37**: 96–97.